

Patient Faces Third Cervical Surgery, Escapes it by Cox® Decompression

Patient Had Cervical, Thoracic, and Lumbar Spine Disc Herniations, All Relieved

This is a case of a 50-year-old, white, married female who was seen on January 10, 2005 for the chief complaint of low back pain, right anterior and posterior thigh and leg pain, thoracic spine pain, and cervical spine and left arm pain. The low back and right leg pain is rated at a 10 on a VAS of 0-10. The thoracic spine pain is an 8 and the neck, shoulder, and arm pain is a 4. Also noted is that the low back pain radiates bilateral into inguinal area and right lateral and anterior thigh to the dorsum of the foot.

History shows that she had surgery of the cervical spine in 1992 and 1997 for spinal stenosis due to osteophytosis and disc herniation. She has had two knee surgeries on the right knee, lithotripsy three times, eye surgery for glaucoma, colonoscopy in 2002, in which polyps were removed, and a history of reflex sympathetic dystrophy following a broken foot in 2004.

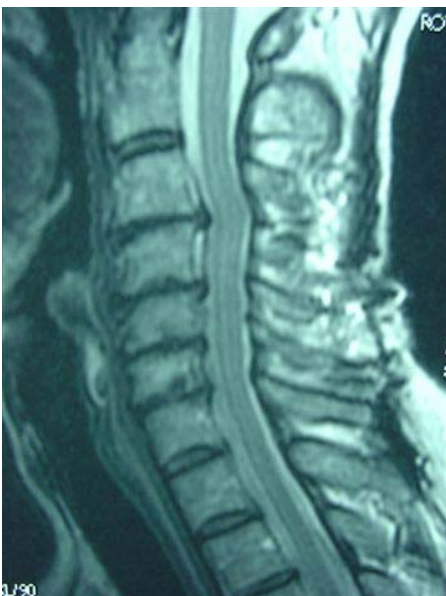
Her mother is alive and suffers with C.O.P.D and her father died of a massive heart attack at age 69.

The patient's blood pressure, heart and lung sounds, and pulse rate are normal. She is oriented x3, alert, anxious about her health, and is found to have an enlarged thyroid for which she is referred to her medical doctor for further evaluation.

This patient saw a physiatrist at a local orthopedic clinic and he immediately said she needed to have cervical spine surgery and fusion performed for a third time. She asked him about seeing me, he said that I was a good doctor, but that I would not be able to help her: however she could go for two weeks and then come back for the surgery.

Examination on 1-10-05 reveals positive sitting straight leg raise to cause low back pain as does Valsalva maneuver. The deep tendon reflexes at the knee and ankle are +2 and the toes are down going. Kemp's is bilaterally positive. Patient can toe and heel walk normally, there is no spinal tilt, the lumbar lordosis decreased. Pain on palpation is noted at all levels, bilaterally, of the lumbar spine. Ranges of motion of the thoraco-lumbar spine are 80 degrees flexion, 10 degrees extension, 10 degrees lateral bending. Sensory examination of the lower extremities reveals hypesthesia of the right L5 and S1 dermatome. The straight leg raise is negative, Lindner causes low back pain and Patrick's test produces bilateral adductor pain. Muscle strength testing of the lower extremities reveals grade 4 of 5 strengths on dorsi and plantar flexion of the foot at the ankle, the great toe, foot eversion, gluteus maximus, biceps femoris, and quadriceps muscles. Yeoman, Ely, Nachlas, and prone lumbar flexion all exacerbate the low back and lower extremity pain.

Cervical spine examination reveals range of motion of 46 degrees flexion, 53 degrees extension, 28 degrees right lateral bending, 45 degrees left lateral bending, and bilateral 30 degrees of rotation. Extreme pain on palpation is noted from occiput through C7 and T1 through T8 bilaterally radiating to the supraspinatous muscle. Hypesthesia of the left C5, C6, and C7 dermatomes is noted. Shoulder range of motion is normal. Muscle strengths of the cervical spine are grade 4 of 5 due to pain in all directions. The deep tendon reflexes at the biceps, bachelioradialis, triceps, and digits are +2. Cervical compression is negative. No carpal tunnel tests signs are positive. The left deltoid, biceps, triceps, interossei, wrist flexors and extensors are grade 4 of 5. No sign of vertebral artery syndrome by George test is found. There is dermatome pain in the C5, C6, and C7 dermatomes of the left arm. Outlet test signs are negative.



IMAGING STUDIES

Figure 1 is a sagittal MRI of the cervical spine. Patient has had two previous cervical disc surgeries for removal of the C5-6 and C6-7 discs. Note that there is advanced degeneration of the C3-4, C4-5, C5-6, and C6-7 disc spaces with protrusions at each level, most marked at C3-C4. Note the contact with the spinal cord at the C3-C4 level. There is a reversal of the usual cervical lordosis at the C2 through C6 levels. The spinal cord reveals no myelomalacia.

Figure 1

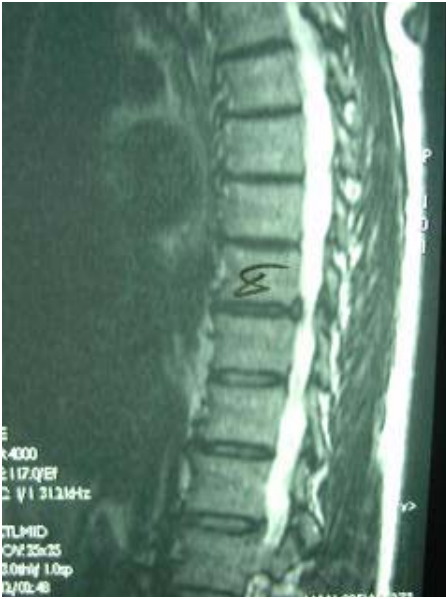

Figure 2

Figure 2 is a sagittal image of the thoracic spine revealing a T8-T9 disc degeneration and herniation.

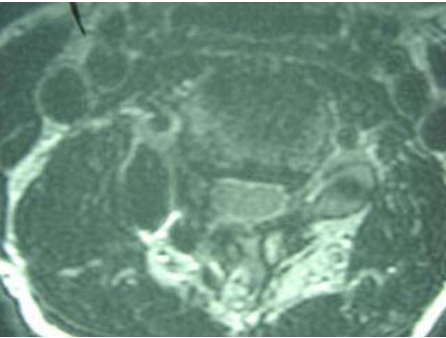


Figure 3

Figure 3 is an axial image at the C6-C7 disc level, which shows no compression of the spinal cord, but there is right posterolateral endplate hypertrophy that minimally narrows the osseoligamentous canal.

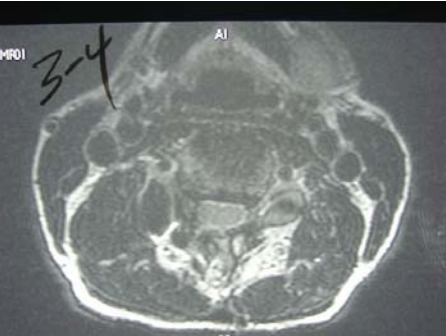


Figure 4

Figure 4 is the axial level at the C3-C4 level, which again shows no spinal cord compression but minimal endplate hypertrophy into the right osseoligamentous canal.

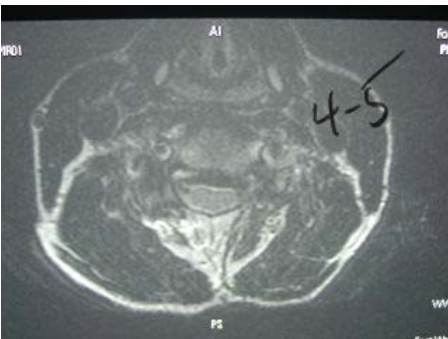


Figure 5

Figure 5 is the axial image at the C4-C5 disc level, which again does not reveal any evidence of spinal cord compression.

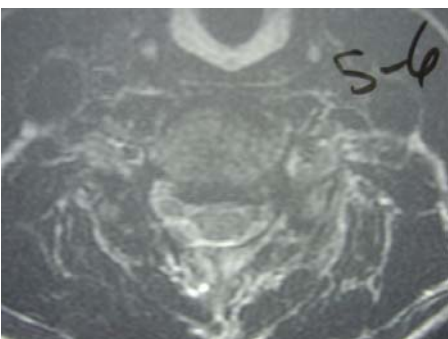


Figure 6

Figure 6 is the axial image at the C5-C6 disc space which does not reveal a broad based endplate hypertrophy which does not contact the spinal cord or cause stenosis of the lateral recesses.

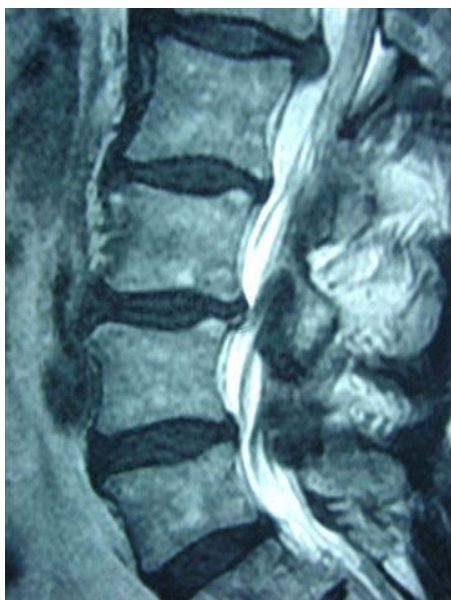

Figure 7

Figure 7 is a T1 weighted sagittal image of the lumbar spine, revealing the L1-L2 and L3-L4 disc herniations as well as stenosis at the L3-4 and L4-L5 levels due to facet arthrosis and ligamentum flavum hypertrophy.

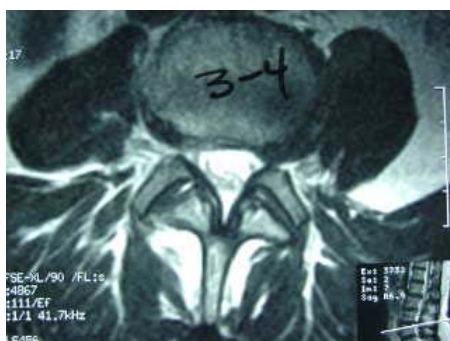

Figure 8

Figure 8 is the axial image at the L3-L4 disc level showing left osseoligamentous canal narrowing due to endplate hypertrophy and disc herniation. There is also facet imbrication on the right side creating stenosis of the lateral recess and osseoligamentous canal.

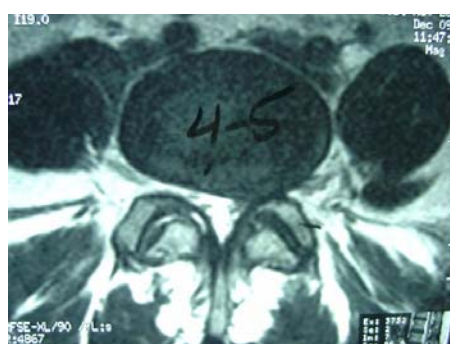


Figure 9

Figure 9 is the axial image the L4-L5 disc level, again showing left osseoligamentous canal stenosis due to endplate hypertrophy and facet imbrication.

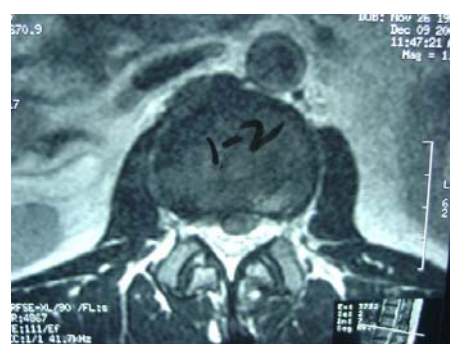

Figure 10

Figure 10 shows the central disc protrusion at the L1-L2 level that does contact the spinal cord.

DIAGNOSIS

The diagnosis in this case was:

1. C3-4, C4-5, C5-6, C6-7 degenerative disc disease and disc herniation at the C3-4 level on sagittal image without any level showing spinal cord compression nor marked recessed stenosis.
2. Past history of surgical discectomy at the C5-6 and C6 levels is noted.
3. L5-S1 degenerative disc disease, L1-L2 herniated disc, and L3-L4 herniated nucleus pulposus.
4. L4-L5 left foraminal stenosis
5. L1-L2 central herniated disc.

TREATMENT

The treatment goals were to relieve pain and inflammation, reduce spasm, reduce herniated disc

material, reduce spinal stenosis with decompression manipulation, and establish a home exercise program of active care, while gradually increasing the patient's activities of daily living. This patient was told that if she is not helped within two weeks that surgery with fusion will be done of her cervical spine.

The treatment used will be Cox® Distraction Decompression, electrical stimulation, alternating hot and cold packs to the cervical spine, massage of trigger points in the neck, shoulders, and arms, and lumbar spine, and she will attend low back wellness school.

She is placed on Discat Plus, 2000mg per day for 3 months, then reduced to 50% of that dose. This is Chondroitin and Glucosamine Sulfate. She is given an herbal pain preparation and also placed on non-phosphorus calcium. She is treated 3 times per week.

CLINICAL OUTCOME

The first visit totally relieved the left arm pain. The right leg pain was 50% reduced.

The treatment continued to be Cox Decompression adjusting of the cervical and lumbar spines followed by electrical muscle stimulation and positive galvanism to the C3 through C7 disc levels and the L1-2, L3-4, and L5-S1 disc levels.

On the second visit, the right leg pain was totally gone, she had no groin pain, and she was tolerating her home exercise and ergonomic training well. The VAS score of the low back had reduced from a 10 to a 4 and the pain of the mid and cervical spine reduced from an 8 to a 4. She had no radicular pain.

Six visits resulted in her only complaint being some left hip pain and thoracic spine pain, which are rated at a 1 on a VAS scale.

The patient missed a week of treatment between January 25 and February 1, 2005, which resulted in her low back and hip pain and cervical spine pain to increase to a VAS of 3 and 4 respectively. One visit resulted in reduction of the pain to a VAS of 1. In 2 visits the pain was zero with only pain in the right knee. An x-ray of the right knee was made which did show medial joint space narrowing with sclerosis of the tibial plateau and some hypertrophy of the intercondyloid eminence with superior patella pole hypertrophy. On February 23, 2005, following a total of 14 visits, this patient has no headache, no neck or arm pain, no thoracic, lumbar spine pain, nor radiating pain into the leg. She does have continued right knee pain due to degenerative arthritis. When last seen she is being seen for a history of polyps of the colon and will be evaluated as a follow up for this diagnosis. An excellent outcome for a patient who was told to have a third cervical spine surgery with fusion. She was told that chiropractic care could not help her. Not only did it help her, but totally relieved her arm pain with one visit. It makes one ask the question- is there a place for decompression manipulation in the treatment of disc herniation, spinal stenosis, and post surgical necks? I think the answer is yes.

Respectfully submitted,

James M. Cox DC DACBR

